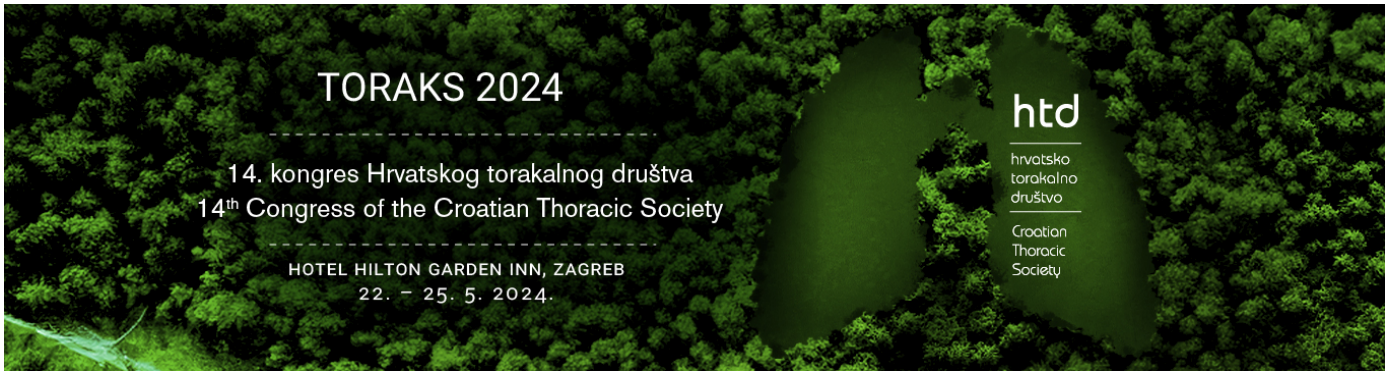

ELEXACAFTOR/TEZACAFTOR/IVACAFTOR: A FIRST CASE OF SEVERE RASH IN CROATIA AND OUR APPROACH TO DESENSITIZATION

VUKIĆ T.[1], Banić M.[1], Darapi D.[1], Rnjak D.[1], Tolić E.[1], Vukić Dugac A.[1]

[1] UHC Zagreb, Zagreb, Croatia
Clinic for Respiratory Diseases Jordanovac

Background:

Elexacaftro/tezacaftor/ivacaftor (ETI) therapy has been the leading treatment option in most adult cystic fibrosis (CF) patients for the last two years. While cough, headache, and fever are common side effects, the appearance of diffuse maculopapular rash is extremely rare. (1)

Conclusion:

Considering significant clinical benefit of CFTR modulators and limited number of treatment options for CF patients, complete discontinuation of therapy is inadvisable. Reintroduction at reduced dose and careful uptitration should always be considered.

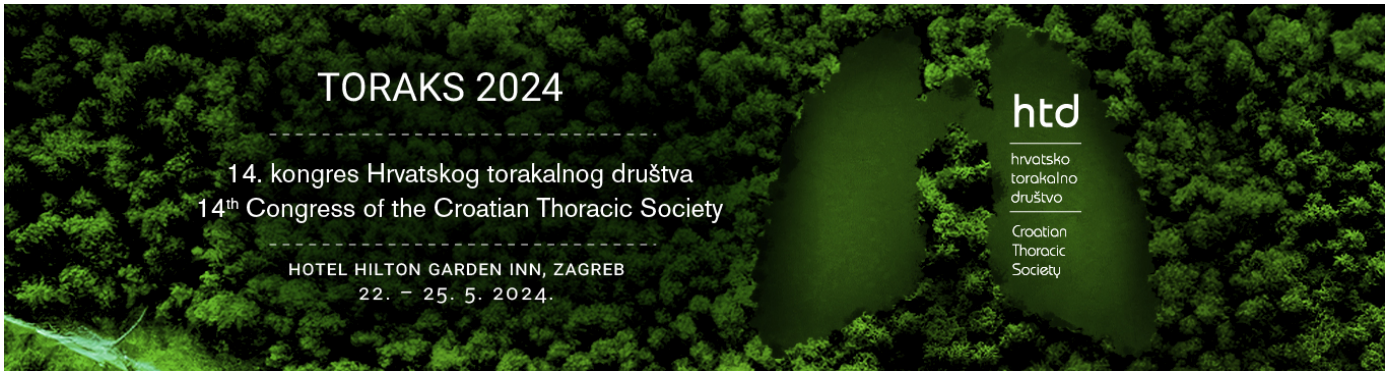

Case:

A 19 y/o female CF patient (F508del/c.345G>C) began ETI therapy in March 2023. Ten days after therapy initiation, she developed diffuse maculopapular rash. The therapy was discontinued and rash resolved over few days. Re-initiation of the therapy in May resulted in rash reappearance the same day. Encouraged by few case reports on drug desensitization, in July 2023 we decided to start a modified 3-day-tolerance induction protocol.

On day 1, premedication with acetylsalicylate (10mg/kg), montelukast (10mg) and cetirizine (10mg) was initiated, followed by gradual induction at 1/1000 ETI tablet, increased every half an hour by half, to 1/32 tablet. Next day, gradual increase of dosage from 1/32 tablet every half an hour by half to ½ tablet. On day 3, the whole tablet was given. The same therapy was administered for four days, when we added the second tablet, achieving the full dosage at day 8. Acetylsalicylate was excluded the second day of full ETI therapy. On day 10 full dose was given without premedication and continued thus far without significant side effects.