

TORAKS 2023

13. kongres Hrvatskog torakalnog društva
13th Congress of the Croatian Thoracic Society

HOTEL WESTIN, ZAGREB
24. – 27. 5. 2023.



RADICAL RIGHT UPPER BILOBECTOMY WITH RESECTION OF FIVE INFILTRATED RIBS AND POLYTETRAFLUOROETHYLENE (PTFE) RECONSTRUCTION OF RIGHT HEMITHORAX-A CASE REPORT

BEČEJAC T.¹, Vrančić M.¹, Danolić D.², Gospić M.³, Draženović D.¹, Tomašić A.³

¹ University Hospital Centre Zagreb, ZAGREB, Croatia
Department of Thoracic Surgery

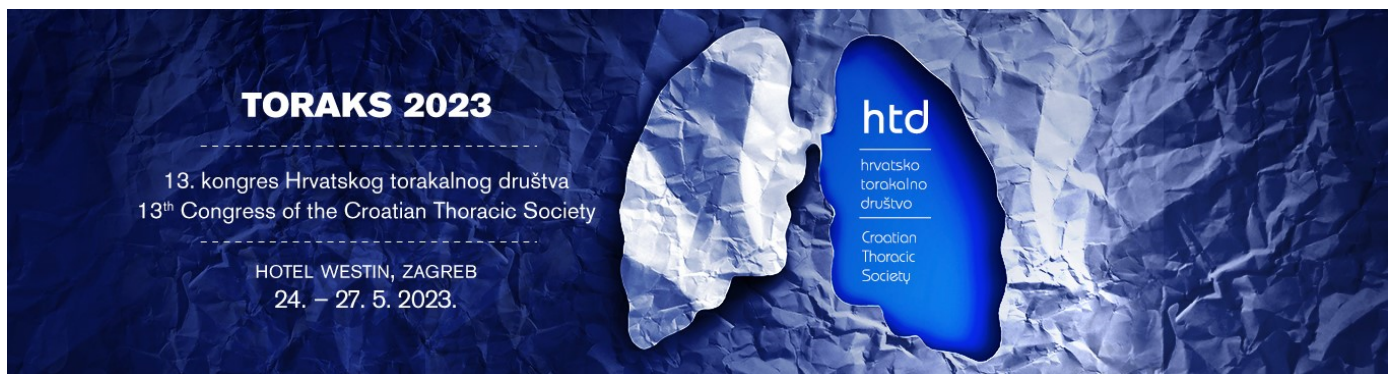
² Sestre Milosrdnice University Hospital Center, ZAGREB, Croatia
University Hospital for Tumours

³ Clinical Hospital Center Rijeka, Rijeka, Croatia
Department of Thoracic Surgery

Objective:

Introduction: Radical lung lobectomies can sometimes be challenging. A need for radical surgical resection with clear borders and margins sometimes requires extensive surgery with ribs resection and reconstruction with a muscle flap or artificial materials like PTFE mesh.

Case report: A 70 years old female patient underwent a chest X-ray and later an MSCT scan because



of pain in the right hemithorax. MSCT scan revealed an expansive process with central necrosis, 57x42mm in size, located in the right upper lung lobe and with infiltration of a third rib. The patient lost 15 kg in three months (24,6% of body weight), BMI was 19,1, NRS 2002 score was 5, Sarc F score was 5. Nutritional supplementation was introduced immediately. In order to determine the metabolic activity of the tumor, hilar and mediastinal lymph nodes, and the degree of dissemination of the potentially malignant disease, a PET/CT scan was performed. In the meantime, tumor size increased to 65x47mm with a SUVmax of 14,8, and pathological accumulation of FDG was detected in right upper paratracheal lymph nodes SUVmax 4,3, suggesting possible dissemination. A bronchoscopy revealed a squamous cell lung carcinoma that was PDL1 negative. Because of the size of the tumor and suspected single station N2 malignant lung disease, an invasive staging of the mediastinum was performed with an EBUS, and no malignant elements were found. A multidisciplinary team indicated operative treatment. Right upper lung bilobectomy with partial resection of I-V rib was performed, with a radical hilar and mediastinal lymphadenectomy and a PTFE reconstruction of a right hemithorax.

Pathohistological analysis confirmed squamous cell lung carcinoma with clear bronchial, vascular, and rib margins and negative mediastinal lymph nodes. Only one hilar lymph node was positive for malignant cells, but with no extranodal tumor spread. The final disease stage was stage IIIA, TNM:T4N1M0. Adjuvant chemotherapy was then indicated, but the patient declined oncological treatment. Six months after surgery, the patient was doing well with a satisfactory chest X-ray and normal lung-specific tumor marker CYFRA 21.1.: 2,44 ug/L.

Conclusions: Radical surgical lung resection is sometimes a very mutilating procedure, and it is mandatory to determine the etiology of a malignant disease and its possible dissemination before the operation. A multidisciplinary team should appoint an indication for a surgical treatment. Good patient preparation for the operation, adequate nutritional support, and prevention of sarcopenia and cancer cachexia are crucial.

TORAKS 2023

13. kongres Hrvatskog torakalnog društva
13th Congress of the Croatian Thoracic Society

HOTEL WESTIN, ZAGREB
24. – 27. 5. 2023.



Keywords: bilobectomy, PTFE reconstruction, sarcopenia